

# *Correlation of clinical outcome and spinopelvic sagittal alignment after surgical treatment of low-grade isthmic spondylolisthesis*

*A. Bourghli, S. Aunoble, O. Reebye & J. C. Le Huec*

**European Spine Journal**

ISSN 0940-6719

Volume 20

Supplement 5

Eur Spine J (2011) 20:663-668

DOI 10.1007/s00586-011-1934-z



**Your article is protected by copyright and all rights are held exclusively by Springer-Verlag. This e-offprint is for personal use only and shall not be self-archived in electronic repositories. If you wish to self-archive your work, please use the accepted author's version for posting to your own website or your institution's repository. You may further deposit the accepted author's version on a funder's repository at a funder's request, provided it is not made publicly available until 12 months after publication.**

# Correlation of clinical outcome and spinopelvic sagittal alignment after surgical treatment of low-grade isthmic spondylolisthesis

A. Bourghli · S. Aunoble · O. Reebye ·  
J. C. Le Huec

Received: 11 July 2011 / Accepted: 11 July 2011 / Published online: 2 August 2011  
© Springer-Verlag 2011

## Abstract

**Introduction** The aim of this prospective study was to assess the sagittal alignment of the spine and pelvis before and after surgical treatment of isthmic spondylolisthesis with flat sacrum. At the same time, the functional outcome was analyzed and correlation examined.

**Materials and methods** This study comprises analysis of 30 subjects (mean age 43 years) with isthmic spondylolisthesis and an average follow-up of 2.5 years after posterior spinal fusion. Radiological spinopelvic parameters were measured and functional evaluation was made using the Oswestry Disability Index.

**Results** Significant improvement toward more normal values for PT and SS in relation to PI was observed after surgery. Pelvic incidence was unaffected by surgery. Correction of the spinosacral angle shows that the anterior tilt with anterior sagittal imbalance due to spondylolisthesis may be corrected by reduction and fusion of the slipped level. Functional outcome was satisfactory with a statistically significant difference between preoperative values and final follow-up values. The sub-group of patients with insufficient restoration of sagittal balance parameters had less good outcomes than the others.

**Discussion and Conclusion** Surgical management of low- and mid-grade isthmic spondylolisthesis showed good clinical outcome with restoration of correct values for the pelvic position-dependent parameters, i.e., pelvis tilt, sacral slope, C7 plumb line position and SSA.

**Keywords** Spondylolisthesis · Outcomes · Pelvic parameters · Isthmic spondylolisthesis · Sagittal balance

## Introduction

It is accepted that a good functional outcome in spinal surgery is largely dependent on restoring a normal sagittal contour [1, 11]. This is achieved by accurately analyzing the sagittal balance on plain preoperative radiographs and calculating the different spinal and pelvic parameters, with the aim of surgery then being to obtain suitable values consistent with patient morphotype as defined by Rousouly et al. [15]. Pelvic incidence, as a morphologic parameter that defines the shape of the pelvis [12], is a key factor in sagittal balance analysis, as well as in the occurrence and progression of spondylolisthesis. Several studies [1, 10] have shown that compared to an asymptomatic population, patients with degenerative, isthmic or developmental spondylolisthesis presented a greater pelvic incidence; thus, depending on pelvis shape and sagittal contour, conditions favoring spondylolisthesis are created.

The aim of this study was to assess the sagittal alignment of the spine and pelvis before and after surgical treatment of isthmic spondylolisthesis while providing analysis of the functional outcome. We hypothesized that achieving a good clinical outcome after surgical treatment for spondylolisthesis involved restoring normal sagittal alignment of the spine.

## Materials and methods

This prospective study included 30 patients (10 males, 20 females), all presenting with low-grade isthmic spondylolisthesis and for whom sagittal balance parameters were analyzed. The aim of surgery was to stabilize the spondylolisthesis segment responsible for radicular and lumbar pain. In all cases, only a posterior procedure involving

A. Bourghli · S. Aunoble · O. Reebye · J. C. Le Huec (✉)  
Spine Unit 2, Bordeaux University Hospital, CHU Pellegrin,  
33076 Bordeaux, France  
e-mail: j-c.lehuec@u-bordeaux2.fr

transforaminal lumbar interbody fusion and pedicular fixation was performed with bone packing or cage insertion. The goal was to restore a normal sagittal contour in relation to each patient's lumbar morphotype [15]. Full spine radiographs in a standardized standing position with fingers of the upper arm overlying the ipsilateral clavicles were taken preoperatively, at the postoperative visit and at regular intervals thereafter. A large majority of image acquisition was performed with an EOS device (Biospace Imaging, Paris, France) and all radiological spinopelvic parameters were measured by two orthopedic surgeons not involved with the care of this cohort of patients (Table 1).

The following radiographic parameters were measured [1]:

*Lumbar lordosis* the angle between the superior end plate of L1 and the end plate of S1.

*Thoracic kyphosis* the angle between the superior end plate of T4 and the inferior end plate of T12.

*Pelvic incidence (PI)* the angle between the perpendicular to the sacral plate at its midpoint and the line connecting this point to the femoral heads axis (Fig. 1a).

*Sacral slope (SS)*: the angle between the horizontal and the sacral plate (Fig. 1b).

*Pelvic tilt (PT)* the angle between the vertical and the line through the midpoint of the sacral plate to the femoral head's axis (Fig. 1c).

*Sagittal vertical axis (SVA)* the distance between C7 plumb line and posterior superior corner on the top margin of S1 (Fig. 2a).

*Spinosacl angle [3] (SSA)*: the angle between a line connecting C7 to the midpoint of the sacral plate and the sacral plate (Fig. 2b).

The degree of slip was measured using the Meyerding classification [4].

The slip angle or lumbosacral angle (LSA) as defined by Dubousset [4]: the angle between the tangent in the posterior edge of S1 and the tangent in the cranial end of L5.

For all sagittal measurements, the angle was considered to be negative if the curve was lordotic and positive if the curve was kyphotic.

Mean operative time and intraoperative bleeding were noted; each patient filled an Oswestry Disability Index preoperatively and during each visit after surgery.

Statistical analysis was made using a *t* test.

## Results

All patients presented with isthmic spondylolisthesis and it involved the L3 level in 1 patient, L4 level in 9 patients and L5 level in 20 patients. All spondylolisthesis levels had a flat end plate at the level of the spondylolisthesis to

differentiate from dysplastic spondylolisthesis. The mean age of patients at the time of operation was 43 years (16–58). One or two levels were fused for each patient, for three patients these were fused without a cage but had bone chips packed in the disc space, and 27 patients had a total of 28 cages (1 patient had 2 cages). Vertebral slippage was improved in all cases by one or two grades on the Meyerding classification after surgery. Mean operating time was 133 min (75–240 min) and mean intraoperative blood loss was 232 mL (50–800 mL).

All patients had a flat vertebral end plate at the level of the spondylolisthesis and none had slippage greater than 50%. The average SVA was 3.8 cm preoperatively and 1.8 cm at the final follow-up. SSA increased from 126.9° preoperatively to 130.13° at the final follow-up. Of 30 patients, 28 had a statistically significant improvement in their Oswestry score of more than 25% at the final follow-up. Four patients had a poor clinical outcome with ODI score less than 25% improvement or worsened. It was always an SPL at level L4L5, the SSA angle was decreased by a mean of 4°, SVA was always positive and worse than preoperatively, and lumbar lordosis always decreased for those four patients. Mean lumbar lordosis increased in a statistically significant fashion between the preoperative and final follow-up measurements ( $p = 0.025$ ): 47° preoperatively (range 19°–80°) and 61° at the final follow-up (range 32°–84°). LSA increased from 108° preoperatively to 111° at the final follow-up, but this increase was not statistically significant. Pelvis tilt decreased from 24.3° preoperatively (range 8°–50°) to 19.9° at the final follow-up (range 10°–39°) without statistical significance. Sacral slope increased from 37.1° preoperatively (range 12°–62°) to 41.8° at the final follow-up (range 17°–62°) without statistical significance. Mean pelvic incidence was 60.9° preoperatively (range 45°–87°) and 61.5° at the final follow-up (range 45°–87°), which is in accordance with the fact that this parameter is a constant anatomical parameter (Fig. 3).

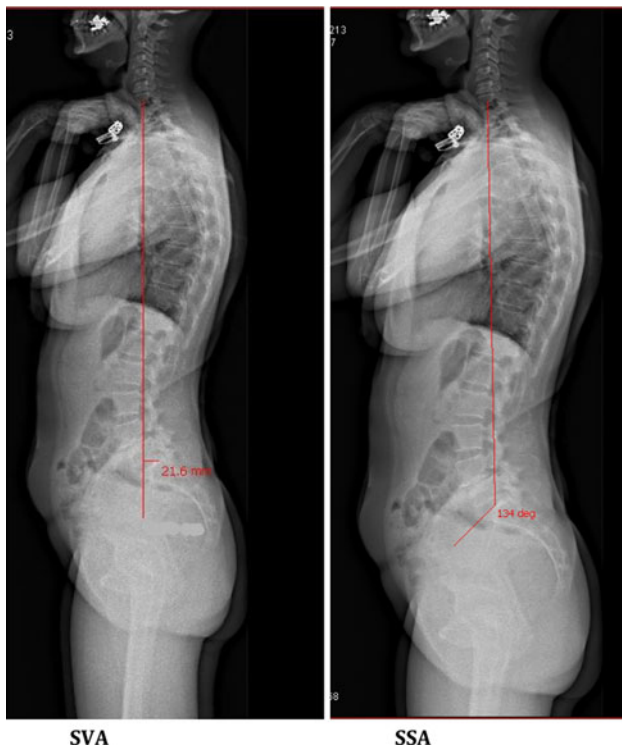
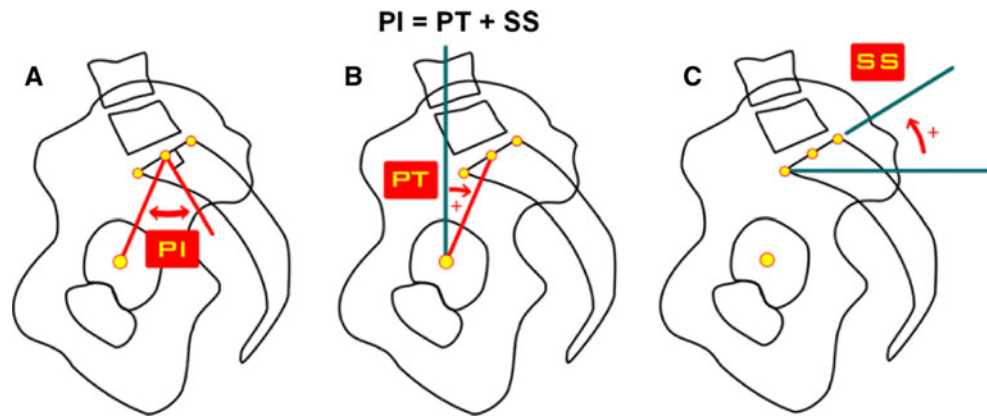
Patients with a low pelvic incidence less than 50° (average 47.3°) were a small group of four. All other patients had a high pelvic incidence with an average PI of 65.3. Mean follow-up was 36 months (range 24–52 months). Clinical outcomes evaluated using the Oswestry Disability Index decreased significantly from the preoperative evaluation to the immediate postoperative evaluation ( $p < 0.0001$ ). The immediate postoperative and final follow-up measurements were also statistically significant ( $p = 0.002$ ). Mean ODI was 43 preoperatively (range 10–66), 20.3 immediately postoperatively (range 0–62) and 16.2 at the final follow-up (range 0–58). If the four bad outcomes with less than 25% improvement in ODI are excluded, the average ODI at the final follow-up is 13.64° (range 0°–34°). In these 26 patients, SSA angle was either maintained or moved closer to the theoretical value of  $135^\circ \pm 7.8^\circ$  as reported by Barrey [1].

**Table 1** Table of values for the series

F-U	Index procedure	Meyering		SVA (cm)		Spinosacral angle		Lumbar lord		Lumbosacral A		Pelvic tilt		Sacral slope		Pelvic incidence		ODI (%)	
		Preop	Postop	Preop	Postop	Preop	Postop	Preop	Postop	Preop	Postop	Preop	Postop	Preop	Postop	Preop	Postop	Preop	Postop
48	L4S1 + TLIF L5S1	1	0	5	3.7	135	136°	30	48°	100	114°	22	25°	36	35°	58	60°	46	22
52	L4S1 + TLIF L5S1	5	2	5	2	110°	115°	19°	39°	42°	93°	42°	24°	21°	35°	63°	59°	40	14
36	TLIF L5S1	2	1	3.5	0	125°	135	74°	84°	92°	100°	8°	18°	56°	44°	64°	62°	60	20
36	TLIF L4L5*	1	0	2	2	120°	118°	53°	48°	110	108	16	19	29	26	45	45	24	46
42	TLIF L5S1	2	1	4.4	-1	142°	145	68°	69	110	110	20	18	60°	62	80°	80	48	18
42	TLIF L4S1	2	1	6	1.2	145	150°	75	80°	120	128°	30	27°	57	60°	87	87°	10	4
44	L4S1 + TLIF L5S1	3	1	4.2	3.6	130°	130°	43.2°	48.8°	124°	140°	18.5	20.6	39.3	35.1	57.8°	55.7°	54	8
42	TLIFL3L5	1	0	9	3	115°	120	34.2°	45	90	105	31	20	28°	39	59.6°	59	58	18
48	TLIF L4L5	1	0	1	-1	140°	138	42	46	112	116	8	10	39	38	47	48	38	0
46	TLIF L5S1	2	1	4	-2.2	122	120°	56°	43°	114°	104°	10	26	40	24	50	50	52	26
42	TLIF L4L5	2	1	1.9	0.9	140°	140°	72°	66.7°	110	107	34	26	49	56	83	82	18	2
36	TLIF L5S1	3	1	4	1.2	125	136°	48	58°	108	130°	26	18°	32	48°	58	66°	24	0
48	L4S1 + TLIF L5S1	2	1	3	-2	135°	136	62°	66°	111°	118°	16°	20	46°	40	62°	60°	42	12
34	TLIF L4L5	1	0	3.2	1.8	125	130°	40	56	120	122	30	25	39	46	69	71°	46	0
34	L4S1 + TLIF L5S1	2	0	4.6	2.1	122	124°	40	50°	100	106°	25	19.1°	23	30.1°	48	49.2°	26	14
30	TLIF L5S1	1	0	3.6	-1.2	130	132	50°	58°	122°	120°	22°	22°	30°	30°	52°	52°	36	10
36	TLIFL5S1	2	0	0	-1.5	140°	142	68.7°	70	120°	130	20.3°	18	38.6°	42	59°	60	58	10
36	L4S1 + TLIF L5S1	1	0	3.5	2.2	125	128°	42	60°	110	114°	35	29°	30	37°	65	66°	32	20
34	TLIF L4L5*	2	1	-1.5	5	142°	130°	70°	62°	120	123	50°	42°	12°	17°	62°	61°	66	58
26	TLIF L4L5*	2	1	1.8	2.4	135°	130°	54.2°	49°	110	114	13°	15°	39°	35°	52°	50°	44	30
26	L3L5 + TLIF L4L5	1	0	10.2	9.6	106°	110°	24.1°	32.7°	100	104	20.8°	19.5°	32.3°	31.2°	53.1°	50.7°	46	22
30	TLIF L5S1	1	0	3.5	-2	135	138	80°	83°	110°	118°	22°	20°	55°	61°	77°	71°	52	18
32	L3L5 + TLIF L4L5*	1	1	4	5.4	112	114°	40	52°	106	109	34	31°	34	38°	68	69°	46	28
32	TLIF L5S1	3	2	2.2	4.1	132°	135	50.8	65	102°	106°	43.7°	39°	38.6°	40°	82.3°	79°	16	0
32	L4S1 + TLIF L5S1	3	3	2	-1.4	120	121°	48°	52°	120°	118°	25	22	36	38	61	60	66	20
30	L4S1 + TLIF L5S1	2	2	1.8	1.6	136°	130°	59°	55°	108°	110°	24.6°	26°	46.8°	39°	71.4°	65°	44	10
30	T12L5 + TLIF L4L5	1	0	13	8.8	114°	114°	41.3°	42°	112	100	32.3°	33°	35.4°	33°	67.6°	66°	52	16
28	L4S1 + TLIF L5S1	2	0	5.7	3.4	150°	154°	63	73	110	120	12°	19.7°	62°	51.7°	74°	71.4°	42	10
24	TLIF L4L5	1	0	3	-1	124°	128	56°	54	102	108	13.2°	10	40.1°	44	53.3	54	52	34
24	TLIF L4L5 L5S1	2	0	2.4	2	142°	140	65.7°	70	96°	100	25°	24	51.5°	53	76.5°	77	52	22

\* Bad clinical outcomes

**Fig. 1** Pelvic parameters. **a** Pelvic incidence *PI*, **b** sacral slope *SS*, **c** Pelvic tilt *PT*



**Fig. 2** SVA sagittal vertical axis: distance between C7 plumb line and posterior corner of S1; SSA spinosacral angle: C7 vertebra—mid part of sacral plateau and the sacral plateau

For the four poor outcomes, SSA angle was unchanged or decreased and SVA was unchanged or increased (Fig. 4).

One patient was reviewed for a deep wound infection 2 months after the index procedure: the material was not removed and total recovery was observed. No pseudarthrosis was noted. Final ODI was 10%.

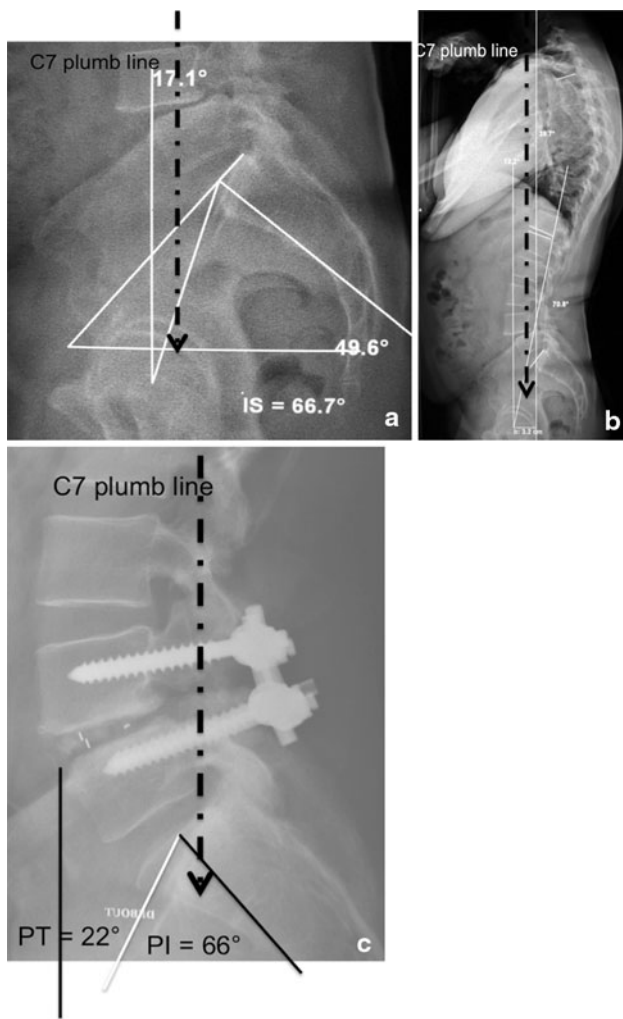
## Discussion

All patients included in this cohort underwent a surgical procedure to treat their spondylolisthesis after failure of

conservative management for back pain and or radicular pain. Several studies [2, 14] have demonstrated the superiority of surgical management with better results regarding disability and pain relief. Nowadays, with our growing knowledge and understanding of the sagittal balance of the spinopelvic unit, it is increasingly clear that adequate management of patients presenting spondylolisthesis is not possible without accurately assessing sagittal balance, and that clinical outcome is closely related to that latter. Analysis of the spine and pelvic parameters should guide us in our treatment to insure postsurgical achievement of suitable values for these parameters in concordance with the patient morphotype according to Labelle's classification. The aim of the surgery is thus to achieve the best spinopelvic sagittal alignment by fusing the level involved, with or without reduction of the spondylolisthesis. Good sagittal alignment is an economical standing position and should minimize muscle work during posture, thereby diminishing pain directly due to excess muscular effort.

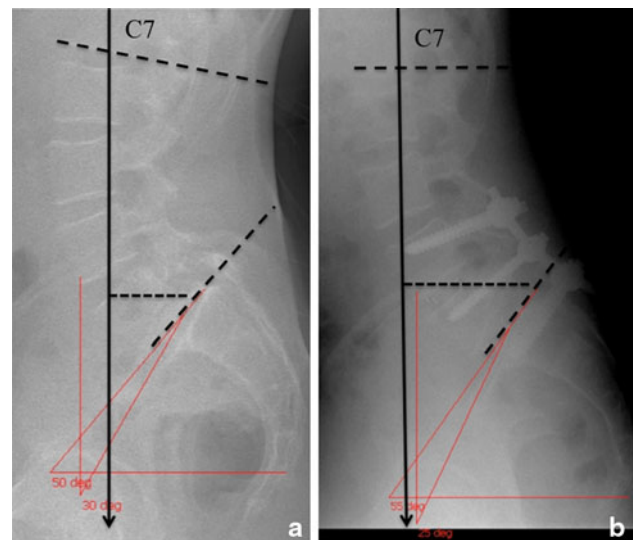
In a retrospective study of 133 high-grade spondylolisthesis patients, Hresko et al. [7] identified two groups of patients with a “balanced” or “unbalanced” pelvis; he suggested that the “unbalanced” category might benefit from reduction of their spondylolisthesis. This paper studied high-grade spondylolisthesis in which sagittal imbalance was more likely to occur and emphasized the fact that analysis of preoperative sagittal alignment is mandatory to understand the spinal biomechanics underlying the disease and to determine whether or not reduction should be considered in the case of spondylolisthesis.

Posterior pelvic tilt in non-dysplastic spondylolisthesis as a compensatory mechanism to sagittal imbalance is now well known. Excessive pelvic tilt has been associated with an increased prevalence of pain after low back surgery [11]. In the present study, analysis of preoperative pelvic tilt values shows that when pelvic tilt is too great (pelvic retroversion), reduction and fusion of the spondylolisthesis reduce the PT value to provide a more physiological value in accordance with pelvic incidence. In a few cases, where



**Fig. 3** Sagittal balance parameter change: when C7 plumb line moves back to a more economical situation for adapted load transmission, the clinical outcome is excellent. **a–c** High pelvic incidence. **a** C7 plumb line directly through the femoral head. Patient tried to restore balance by hyperlordosis of 78° lordosis with kissing spinous processes, but there was a limit. The L4 vertebra is in hyperextension with the disc open anteriorly. This was painful and not economical, OSW: 66. **b** full spine lateral view. **c** Postoperatively: sacrum is more vertical with decreased sacral slope and PT increased to reach normal value in accordance with the pelvic incidence (66°) and C7 plumb line moved backward restoring an economical balance. Lumbar lordosis decreased to 68° and spinous processes were not touching. Economical balance OSW: 12

the PT was initially very low, the surgical procedure increased these values, giving higher values compatible with the generally high PI observed in this category of patients. The differences between preoperative and postoperative values are not highly statistically significant, as there is no major sagittal imbalance in this series given the fact that the study included only mid- and low-grade but not high-grade spondylolisthesis. The spinosacral angle improved postoperatively toward a more normal value with significance at  $p < 0.04$ .



**Fig. 4** SPL L5S1, TLIF L4L5 + L5S1. Bad restoration of lumbar lordosis. **a** 80°, **b** 65, Pelvis Tilt unchanged but C7 plumb line moved forward, SVA worst: 2 preop, 5 post: bad outcome

In summary, in our study, a trend toward more normal values of PT and SS in relation to PI was observed after surgery. Correction of the spinosacral angle shows that the tendency toward anterior sagittal imbalance due to spondylolisthesis may be corrected by reduction and fusion of the slipped level. Use of a cage at the level concerned probably contributes to the improvement in lumbar lordosis by increasing segmental lordosis, and the difference between preoperative and postoperative values for this parameter is significant. Lumbar lordosis reached a value close to the theoretical value based upon pelvic incidence [16]. Pelvic incidence was unaffected by surgery, which is normal given the fact that it is a morphologic parameter that defines the shape of the pelvis and that it can be only modified by pelvic osteotomy. Lumbar lordosis was less modified when listhesis occurred at level L4L5. Lumbar lordosis restoration seemed better correlated with Pelvic incidence when SPL occurred at level L5S1.

In another paper, Hresko [6] suggested that achievement of solid arthrodesis by partial reduction and instrumentation may be the most important determinant of outcome, as no correlation was found in his series between the amount of reduction of spondylolisthesis and the improvement in pelvic tilt. Functional outcome was satisfactory, with a statistically significant difference between preoperative values and the last follow-up values in our series (43 preoperative to 16.2 at last follow-up). A meta-analysis by Kwon et al. [8] showed a better outcome for treatment of isthmic spondylolisthesis using instrumented posterior spinal fusion in combination with an interbody graft as opposed to either PSF treatment alone or interbody graft alone. The positive impact of interbody support in the

surgical treatment of spondylolisthesis on radiographic and clinical outcomes has been confirmed by Molinari [13]. A study by Labelle et al. [9] concerning high-grade L5/S1 developmental spondylolisthesis showed that postoperative improvement in L5 incidence and slip angle was correlated with a better outcome, while subjects with a poor outcome had a higher preoperative grade. The author suggested that the key to a successful outcome after surgery appeared to be the repositioning of L5 over S1 as measured by L5 incidence and lumbosacral angle (LSA), rather than correction of the grade. In our study, LSA improved after surgery, moving toward a more normal value, without statistical significance, but the moderate improvement in LSA showed that L5 repositioning occurred.

Our results are similar to those mentioned by Goyal [5] in a study analyzing mid- and high-grade isthmic spondylolisthesis, in which improvement was noted in anterolisthesis and sacral inclination after PSF with TLIF with a good clinical outcome; detailed analysis of the sagittal balance was not performed in this paper and we emphasize the importance of using pelvis tilt in association with sacral slope when analyzing the pelvic parameters during the preoperative planning of spondylolisthesis. Use of the spinosacral angle is advisable to assess the global balance of the spine, especially in mid- and high-grade spondylolisthesis. However, SSA measurement is not possible in the case of a dome-shaped sacral plateau. The fusion rate could have been evaluated by CT scan controls at the fused levels, but this was not done due to the good clinical outcomes.

Sagittal vertical axis distance showed that all patients with good clinical outcomes had a reduction of this one and the four patients with poor outcome had a same or increased SVA showing that in the case of the C7 plumb line moving forward, the balance is worst and the patient in not in an economical situation.

## Conclusion

Surgical management of low- and mid-grade isthmic spondylolisthesis showed good clinical outcome with restoration of correct values for the pelvic position-dependent parameters, i.e., pelvis tilt, sacral slope and SVA. Lumbar lordosis in accordance with pelvic incidence is also important. Preoperative planning should include an accurate radiological study of the pelvis to assess the impact of the spondylolisthesis on global sagittal balance. Pelvic parameters have an important role not only in defining patient spinopelvic morphotype, but also with regard to control and regulation of global balance and postoperative alignment. In a flat sacral plateau, SSA measurement provides a good global evaluation for success as the angle is an intrinsic parameter of global spinal balance, especially in mid- and

high-grade spondylolisthesis. SVA is adequate in all cases to evaluate global balance pre- and postoperatively.

**Conflict of interest** None.

## References

1. Barrey C, Jund J, Perrin G, Roussouly P (2007) Spinopelvic alignment of patients with degenerative spondylolisthesis. *Neurosurgery* 61:981–986
2. Carreon LY, Glassman SD, Howard J (2008) Fusion and non-surgical treatment for symptomatic lumbar degenerative disease: a systematic review of Oswestry Disability Index and MOS Short Form-36 outcomes. *Spine J* 8:747–755
3. Debarge R, Demey G, Roussouly P (2009) Radiological analysis of ankylosing spondylitis patients with severe kyphosis before and after pedicle subtraction osteotomy. *Eur Spine J* 19:65–70
4. Dubousset J (1997) Treatment of spondylolysis and spondylolisthesis in children and adolescents. *Clin Orthop Relat Res* 337:77–85
5. Goyal N, Wimberley DW, Hyatt A, Zeiller S, Vaccaro AR, Hilibrand AS, Albert TJ (2009) Radiographic and clinical outcomes after instrumented reduction and transforaminal lumbar interbody fusion of mid and high-grade isthmic spondylolisthesis. *J Spinal Disord Tech* 22:321–327
6. Hresko MT, Hirschfeld R, Buerk AA, Zurakowski D (2009) The effect of reduction and instrumentation of spondylolisthesis on spinopelvic sagittal alignment. *J Pediatr Orthop* 29:157–162
7. Hresko MT, Labelle H, Roussouly P, Berthounaud E (2007) Classification of high-grade spondylolistheses based on pelvic version and spine balance: possible rationale for reduction. *Spine* 32:2208–2213
8. Kwon BK, Hilibrand AS, Malloy K, Savas PE, Silva MT, Albert TJ, Vaccaro AR (2005) A critical analysis of the literature regarding surgical approach and outcome for adult low-grade isthmic spondylolisthesis. *J Spinal Disord Tech* 18(Suppl):S30–S40
9. Labelle H, Roussouly P, Berthounaud E, Dimnet J, O'Brien M (2005) The importance of spino-pelvic balance in L5–s1 developmental spondylolisthesis: a review of pertinent radiologic measurements. *Spine* 30(Suppl):S27–S34
10. Labelle H, Roussouly P, Chopin D, Berthounaud E, Hresko T, O'Brien M (2008) Spino-pelvic alignment after surgical correction for developmental spondylolisthesis. *Eur Spine J* 17:1170–1176
11. Lazennec JY et al (2000) Sagittal alignment in lumbosacral fusion: relations between radiological parameters and pain. *Eur Spine J* 9:47–55
12. Legaye J, Duval-Beaupere G, Hecquet J, Marty C (1998) Pelvic incidence: a fundamental pelvic parameter for three-dimensional regulation of spinal sagittal curves. *Eur Spine J* 7:99–103
13. Molinari RW, Bridwell KH, Lenke LG, Baldus C (2002) Anterior column support in surgery for high-grade, isthmic spondylolisthesis. *Clin Orthop Relat Res* 394:109–120
14. Moller H, Hedlund R (2000) Surgery versus conservative management in adult isthmic spondylolisthesis—a prospective randomized study: part 1. *Spine* 25:1711–1715
15. Roussouly P, Gollogly S, Berthounaud E, Dimnet J (2005) Classification of the normal variation in the sagittal alignment of the human lumbar spine and pelvis in the standing position. *Spine* 30:346–353
16. Schwab F, Lafage V, Patel A, Farcy JP (2009) Sagittal plane considerations and the pelvis in the adult patient. *Spine* 34:1828–1833